



Can TASER Electronic Control Devices Cause Cardiac Arrest?

TASER Electronic Control Devices Can Cause Cardiac Arrest in Humans

Douglas P. Zipes, MD



The TASER X26 electronic control device (ECD) is a handgun-shaped device that uses compressed nitrogen to fire darts ranging from 9 to 14 mm in length that impale the clothes or skin of an individual up to a distance of 35 ft. Wires connect the darts to the device. The TASER X26 functions as a constant current generator and delivers an initial 50000-V to begin an arcing shock (the actual voltage delivered to the body is in the range of 1400–2520 V), followed by electric pulses of 105- to 155-microsecond duration, at a frequency of \approx 19 Hz (\approx 1140 times per minute), and 80- to 125-microcoulomb delivered charge.¹ A single trigger pull discharges a 5-second cycle that can be shortened by a safety switch to deactivate the device or prolonged if the trigger pull is held. The trigger can be activated multiple times. The X26 data port stores the time and date of use and number and duration of trigger pulls. If effective, the shock elicits neuromuscular inhibition, allowing law enforcement to gain control of a suspect (see www.youtube.com/watch?v=ACUjnJBHIZc for a TASER demonstration). The device can also be applied in a “drive-stun” mode by directly pressing the X26 ECD against the skin to achieve pain compliance without neuromuscular inhibition. The TASER X26 is the most widely sold ECD. Called a less lethal or nonlethal weapon because it is supposed to be deployed to temporarily incapacitate, not to kill the subject, the X26 is not considered a firearm and therefore is not regulated by the Bureau of Alcohol, Tobacco, Firearms and Explosives.

Response by Kroll et al on p 111

Purpose

The purpose of this article is to present information to support the conclusion that the TASER X26 ECD can cause cardiac arrest in humans. As noted in an earlier article,² the purpose is not to offer an opinion about whether the use of TASER or any other ECD product is appropriate because I think that decision belongs to trained law-enforcement professionals, not physicians.

Background

A previous publication² presented 8 cases of sudden cardiac arrest that, in my opinion, resulted from delivery of electric impulses generated by a TASER X26 ECD. None had manifest cardiovascular symptoms, although several had non-cardiac-related medical problems, including alcohol abuse, attention deficit disorder, mental confusion that was possibly postictal from a seizure, and depression/schizophrenia. At autopsy, several were alleged to have had underlying heart disease (Table). All had rapid loss of consciousness after X26 deployment and ECD shocks via 1 or more darts in the anterior chest (Figures 1 and 2). Selected ECGs recorded at various time intervals during resuscitation attempts showed ventricular tachycardia (VT)/ventricular fibrillation (VF) in 5, a shockable rhythm by an automated external defibrillator in

The opinions expressed in this article are not necessarily those of the editors or of the American Heart Association.

From the Indiana University School of Medicine, Indianapolis.

This article is Part II of a 2-part article. Part I appears on p 93.

The online-only Data Supplement is available with this article at <http://circ.ahajournals.org/lookup/suppl/doi:10.1161/CIRCULATIONAHA.113.005504/-/DC1>.

Correspondence to Douglas P. Zipes, MD, Distinguished Professor, Krannert Institute of Cardiology, Indiana University School of Medicine, 1800 N Capitol Ave, Indianapolis, IN 46202. E-mail dzipes@iu.edu

(*Circulation*. 2014;129:101-111)

© 2014 American Heart Association, Inc.

Circulation is available at <http://circ.ahajournals.org>

DOI: 10.1161/CIRCULATIONAHA.113.005504

**Table. Summary of the 8 Cases Reported as Having Cardiac Arrest After X26 Administration**

Case	Age, y	Height/ Weight, lb	Length of ECD Shock(s), s	Response to ECD Shock	Time to Initial ECG After ECD Shock, min	Initial Recorded Rhythm	Drug Screen	Cardiac Findings at Autopsy	Comments
1	48	6 ft 0 in/155	5, 8, 5	LOC toward end of last ECD cycle	Several	VT/VF	BAC 0.35 g/100 mL; THC present	Survived with memory impairment; normal echocardiogram	5 AED shocks, intravenous epinephrine, and lidocaine eventually restored a perfusing rhythm
2	17	5 ft 7 in/170	37, 5	LOC toward end of a 37-s cycle	>4.5	VF	Negative	410 g; focal atherosclerosis; plaintiff pathologist: normal; defense pathologist: HCM	3 defibrillating shocks and an additional 3 shocks from a second AED at least 9 min after the collapse failed to resuscitate
3	17	5 ft 8 in/115	5	ILOC	>5	VF	BAC 0.25 g/100 mL; THC present	270 g; normal heart	Asystole developed after the AED shock and then PEA; subsequently, VF recurred and a second AED shock was delivered, followed by asystole/ PEA; could not be resuscitated
4	24	5 ft 10 in/176	11	ILOC	≈10	AED: "shockable rhythm"; asystole after shock; no recordings available	BAC 0.319 g/100 mL	400 g; plaintiff pathologist: no specific pathology; defense pathologist: lymphocytic myocarditis	Said to be breathing initially with a weak radial pulse; resuscitated in hospital; life support withdrawn after 3 d because of anoxic encephalopathy
5	33	6 ft 2 in/220	13 shocks totaling 62 s in <3 min	LOC toward the end of multiple shocks	≈13	Fine VF vs asystole	Gabapentin 31 μg/mL	470 g; 10%– 20% narrowing of the LAD; normal histology	Gabapentin taken for seizure disorder
6	24	5 ft 6 in/144	49, 5	LOC toward end of 49-s shock	≈10	VT/VF	Negative	366.7 g; normal gross and microscopic findings	Said to be breathing initially; could not be resuscitated
7	16	5 ft 3 in/130	5	ILOC	≈10	VT/VF	THC	380 g; medical examiner diagnosis: right ventricular cardiomyopathy, disputed by plaintiff's expert	6 AED shocks for VT/VF resulted in asystole/PEA; could not be resuscitated
8	23	5 ft 9 in/173	21, 7, 3	LOC toward end of 21-s shock	≈30	Asystole	BAC 0.111 g/100 mL	400 g; mild interstitial fibrosis of compact atrioventricular node; interstitial fibrosis, atrophy, and vacuolization of penetrating and branching bundle	Said to be breathing with pulse initially; could not be resuscitated; cardiac pathologist could not determine whether changes contributed to death

AED indicates automated external defibrillator; BAC, blood alcohol concentration; ECD, electronic control device; HCM, hypertrophic cardiomyopathy; ILOC, immediate loss of consciousness during/after initial shock; LAD, left anterior descending coronary artery; LOC, loss of consciousness during/after initial shock; PEA, pulseless electric activity; THC, tetrahydrocannabinol, positive screen for marijuana; VF, ventricular fibrillation; and VT, ventricular tachycardia. Heart weight is given in grams. Gabapentin is Neurontin.

Reproduced from Zipes DP. Sudden cardiac arrest and death following application of shocks from a TASER electronic control device. *Circulation*. 2012;125:2417–2422.²

1 (no ECG recording), fine VF/asystole in 1, and asystole in 1 (Figure 3). The last 2 cases had significant time delays from X26 deployment and loss of consciousness until ECGs were recorded (Figures 4 and 5). Only 1 of 8 was resuscitated but with residual anoxic cognitive impairment.

In an accompanying editorial, Myerburg et al³ stated that the article established "proof of concept" and that the information in at least 2 of the cases lent "...credence to the likelihood of an association that is strong enough to demonstrate a cause-and-effect relationship."

Case 3: 17-year-old

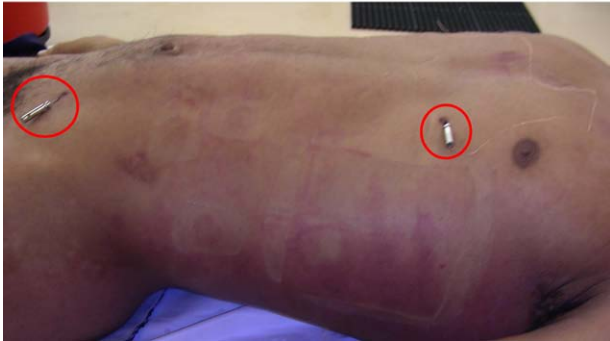

Figure 1. Picture at autopsy of case 3 with TASER X26 barbs still in place (circles). The heart at autopsy was normal.

After publication, 3 Letters to the Editor by physicians having TASER relationships disputed aspects of single cases but not the overall concept of TASER-induced VF. As I concluded in my response to those letters,⁴ "...the published body of evidence now makes it perfectly clear that a TASER X26 ECD shock can induce VF in humans, transforming the argument from if it can happen to how often it happens."

Cases 7 and 8 from the original article² are expanded here to demonstrate causality and to make several points.

Case 7

A 16-year-old black boy (body mass index [BMI] 23 kg/m²) with attention deficit disorder and asthma but without previous cardiac history or symptoms of heart disease ran ≈290 yd to an abandoned house. Confronted by police, possibly sweating, he received a 5-second chest shot with a TASER X26 from 3 to 4 ft away, immediately dropped to the ground, and was unconscious and unresponsive. One officer noted transient moaning and an apparent seizure ≈30 seconds after the shock and found no carotid pulsations or respirations. After 1 to 1½ minutes of cardiopulmonary resuscitation [CPR], the officer noted a carotid pulse and spontaneous respirations that

Case 7: 16-year-old

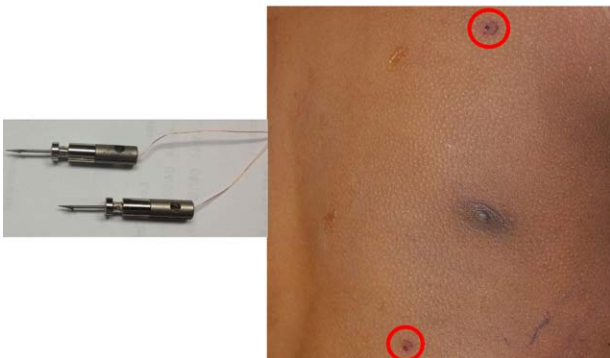


Figure 2. Left, Picture of 12.2- and 13.2-mm TASER X26 darts used in case 7 after removal from the skin. Right, Picture of TASER X26 dart marks (circles) above and below the left nipple of case 7. The head is at the top.

Selected ECGs during resuscitation for 7 of the 8 cases.

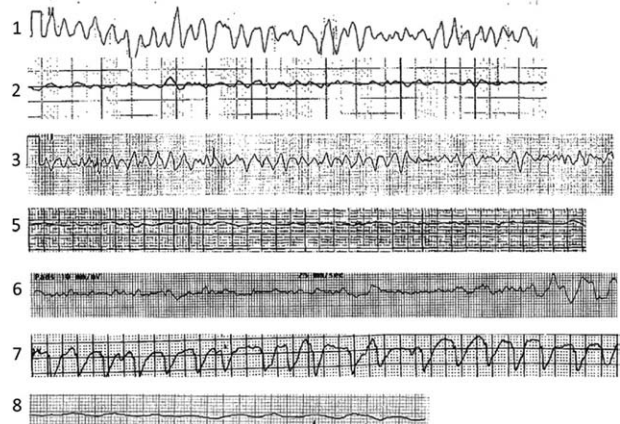


Figure 3. Selected ECGs recorded during resuscitation attempts in 7 of the 8 cases. Reproduced from Zipes. Sudden cardiac arrest and death following application of shocks from a TASER electronic control device. *Circulation*. 2012;125:2417–2422.²

lasted ≈15 seconds before ceasing spontaneously, and CPR was resumed. The first recorded ECG ≈8 minutes after the X26 shock showed VF. He was then defibrillated 4 times at 300 J and once or possibly twice at 360 J. He could not be resuscitated and was pronounced dead after transportation to the hospital. Autopsy showed 2 skin marks separated by 5¼ inches, consistent with TASER dart marks, 3 inches above and 2 inches below the left nipple (Figure 2 right). Dart length was 12.2 and 13.2 mm (Figure 2, left). The heart was slightly enlarged at 380 g, and the subject was diagnosed as having arrhythmogenic right ventricular cardiomyopathy (ARVC) by the forensic pathologist/medical examiner, who stated it was unknown whether the "taser [sic] device resulted in a direct effect on the heart or whether it served to exacerbate an

Case 8: 23-year-old before and after TASER X26 deployment



Figure 4. Case 8: still frames taken from video by police camera before and after TASER X26 administration. Initially, the man struggled with police (left). Off camera, he received X26 shocks of 21-, 7-, and 3-second duration and was then brought back into the video field by police (right). He was nonresponsive and gasping for breath, most likely agonal breathing. Note head at bottom of frame when he was unconscious, likely due to ventricular fibrillation. For full video, see Movie I in the [online-only Data Supplement](#).

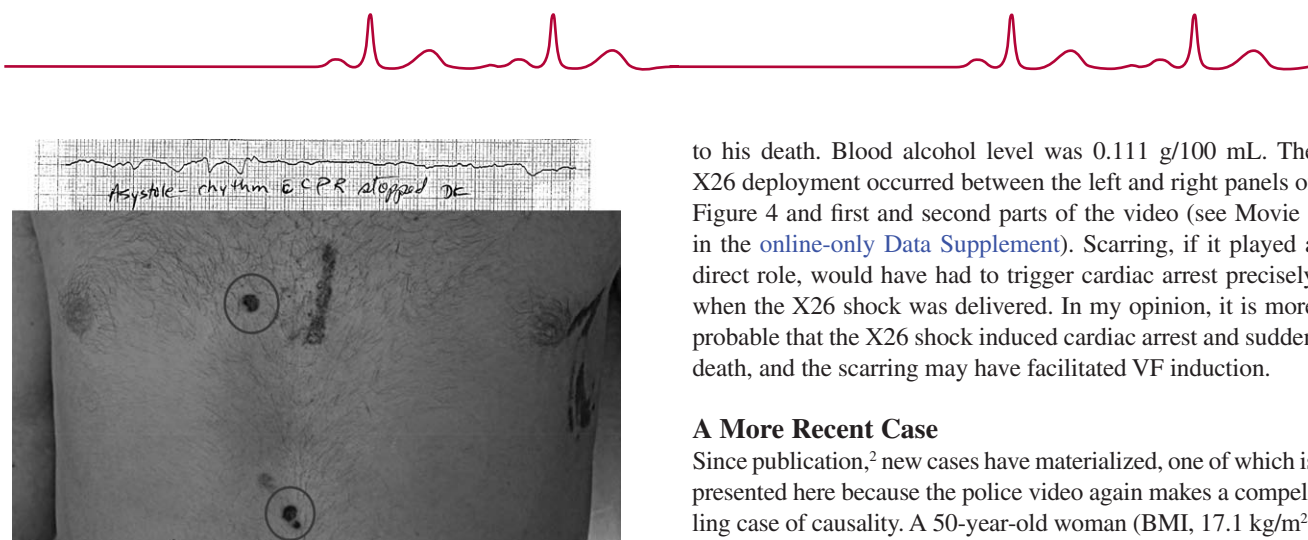


Figure 5. Top, ECG during resuscitation attempt. Bottom, Picture of case 8 at autopsy showing TASER X26 barb marks (circles).

arrhythmia....” A second pathologist agreed with the diagnosis of ARVC and stated that the “TASER ECD played no significant role in his death.” Another forensic pathologist detected “no convincing morphologic finding that can be construed as evidence of a preexisting abnormality of his heart” and indicated that the individual “...died as a result of an electric injury brought about by direct discharge of the Electronic Control Device....” Still another found that he did not have ARVC and that cause of death was a “cardiac dysrhythmia associated with the use of an electronic control device...a TASER.” Marijuana was the only drug found. He had been prescribed atomoxetine for attention deficit disorder, but its role, if any, is uncertain. Regardless of whether this young man had ARVC, he sustained a 5-second X26 chest shock with extra penetration darts near his heart (Figure 2), immediately lost consciousness, was noted to have VF \approx 8 minutes later, and could not be resuscitated. If the alleged ARVC played a direct role, it would have had to trigger VF precisely when the X26 shock was delivered. In my opinion, it is more probable that the X26 shock caused the VF and subsequent death, and if the alleged ARVC was actually present, it facilitated VF induction.

Case 8

The police video (Figure 4 and Movie I in the [online-only Data Supplement](#).) for this case helps establish causality. A 23-year-old white man (BMI, 25.5 kg/m²) with no history of heart disease or cardiac symptoms struggled briefly with police officers after a traffic stop. He moved out of camera range for several minutes and received 3 X26 shocks of 21, 7, and 3 seconds. One police officer said the young man fell face forward after the first shock and was given a second shock because he could not or would not remove 1 of his hands from beneath his chest to be handcuffed. He was then carried back into camera range and propped curbside by police (Figure 4). Police officers said he initially was breathing and had a pulse. Despite CPR, an ECG recorded many minutes later documented asystole. At autopsy (Figure 5), cardiac scarring was noted (Table), but the cardiac pathologist could not state whether that contributed

to his death. Blood alcohol level was 0.111 g/100 mL. The X26 deployment occurred between the left and right panels of Figure 4 and first and second parts of the video (see Movie I in the [online-only Data Supplement](#)). Scarring, if it played a direct role, would have had to trigger cardiac arrest precisely when the X26 shock was delivered. In my opinion, it is more probable that the X26 shock induced cardiac arrest and sudden death, and the scarring may have facilitated VF induction.

A More Recent Case

Since publication,² new cases have materialized, one of which is presented here because the police video again makes a compelling case of causality. A 50-year-old woman (BMI, 17.1 kg/m²) with no manifest heart disease received a reported 3 X26 shocks to the left chest, with darts just above and below the left breast (based on dart marks noted subsequently). After the third X26 trigger pull reported by 1 officer, she immediately lost consciousness (video link of the X26 application can be found at <http://www.youtube.com/watch?v=b6dHpt6c6zM>) and started seizing. CPR was begun 6 minutes later, and an automated external defibrillator was applied 12 minutes after the X26 shock. After a shock for VF, she had return of sinus rhythm, breathed on her own, and survived, apparently with some memory deficit. Her drug screen was positive for cannabinoids but otherwise negative. Echocardiography shortly after resuscitation showed left ventricular end-diastolic dimension of 5.4 cm, estimated ejection fraction of 40%, mild to moderate mitral regurgitation with annular calcification, and mild to moderate tricuspid regurgitation consistent with myxomatous degeneration. Subsequent echocardiography showed normal LV size and systolic function, EF 55% to 60%, with thickened mitral and aortic valves, indicating most of the changes were likely related to the cardiac arrest. As in the 2 cases discussed above, this individual was fully active and conscious until receiving the X26 shock and then had a cardiac arrest caused by VF. If underlying heart disease played a direct role, it would have had to trigger VF precisely during the X26 shock. In my opinion, it is more probable that the X26 shock induced cardiac arrest and that any underlying cardiac pathology facilitated VF induction.

Incidence

The issue of how often cardiac arrest happens noted in my letter above is critical to establish the degree of risk. Amnesty International noted 334 deaths after an ECD shock between 2001 and 2008,⁵ which increased recently to 544.⁶ Although all in-custody deaths after ECD shocks are not likely a direct result of the shock, a number probably are. TASER International addressed that probability by revising their warnings from “aim at target: center of mass or legs” and “aiming at open front of unzipped jacket” before September 2009⁷ to “when possible, avoiding chest shots...” after that date.⁸ More recently, they noted that “heart rate, rhythm, capture” can occur and that “capture” and “cardiac arrest” can contribute to arrest-related death in physiologically or metabolically compromised persons.⁹



TASER counsel indicated that the risk of an ECD causing cardiac arrest was on the order of 1:100000 applications.¹⁰ Given an estimated 3 million TASER ECD applications,¹⁰ this would compute to ≈ 30 deaths. However, the actual incidence of cardiac capture and cardiac arrest, and therefore the risk for this to occur, cannot be determined accurately for several reasons. First, as noted below, in the 2 instances of documented TASER ECD cardiac capture in humans, the individuals were totally asymptomatic during the 5- and 10-second exposure cycles. Thus, it is possible that transient cardiac capture occurs in the field but goes unnoticed if it does not result in cardiac arrest.

The second reason is the lack of accurate numbers to calculate incidence because no mandatory reporting exists in the United States. A bill requiring such reporting, for which I gave supporting testimony, was recently defeated by the Connecticut legislature (CGA H.B. No. 6628; 2013). The total number of TASER deployments is irrelevant because how often an individual is shot in the buttocks, abdomen, extremities, or back is of no cardiac concern. The number of chest shots is the important metric. One study¹¹ found that of 813 probe deployments, 21.9% had anterior chest placements. Obtaining an accurate estimate of incidence of death, and therefore risk from the TASER, would require an accurate estimate of the total number of deaths (numerator), a potentially underreported value, and the total number of chest shots (denominator), which is unknown. A recent article in the British newspaper *The Guardian* reported that of 884 TASER deployments from 18 of 45 UK forces since 2009, which was when TASER's warnings about avoiding chest shots were published,⁸ 518 (59%) of all shots have hit the chest area.¹²

Animal Research

The most compelling evidence to prove the assertion made in the title of this article would be to record the development of VT/VF from a human during an X26 shock. This is very difficult for 2 reasons: The individual would require a cardiac recording device already in place during the shock, and the electric interference from the X26 could make any ECG recording unreadable. Therefore, animal studies become a necessary substitute.

A study in 2006¹³ demonstrated that 5-second shocks from the equivalent of a standard TASER X26 ECD delivered via 9-mm darts inserted in various chest positions of anesthetized pigs caused cardiac capture, documented by an intracavitary right ventricular recording electrode. Dart vectors influenced capture. A position more likely to cause capture was from the sternal notch to the cardiac apex, resulting in ventricular capture ratios ranging from 6:1 to 3:1 (190–380 bpm). No VF occurred with normal output, but an increase in ECD power decreased the capture ratio, and VF consistently resulted when the ventricular capture ratio was $\leq 2:1$. The authors noted that the data suggested

...the potential for induction of ventricular tachycardia in subjects with substrate for ventricular tachycardia.... Avoidance of this position would greatly reduce any concern for induction of ventricular arrhythmias.¹³

A second study using an off-the-shelf TASER X26 with a right ventricular recording lead showed that 52 of 53 discharges (98.11%) to the porcine chest caused cardiac capture, whereas 0 of 56 nonthoracic discharges stimulated the heart.¹⁴ As with the prior study,¹³ blood pressures fell to very low values at rapid capture rates. During epinephrine infusion to increase the spontaneous heart rate 50% to simulate the agitated stress state of an individual experiencing pain or resisting restraint, 13 of 16 TASER X26 discharges caused cardiac capture, 1 caused nonsustained ventricular tachycardia that spontaneously reverted to sinus rhythm, and 1 caused VT that evolved to VF and cardiac arrest (Figure 6).

In a series of 3 studies using 12-mm darts, investigators exposed pigs to two 40-second discharges from a TASER X26 ECD separated by a 10-second pause with ventilation between shocks. Five minutes after the shocks, pigs were profoundly acidotic with pH values of 6.86. One pig developed 3 minutes of sustained, monomorphic VT after the ECD discharge before finally progressing to VF (Figure 7).¹⁵ After a left anterior thoracotomy to video the heart during the ECD shock, another pig developed VT preceding to VF (<http://www.youtube.com/watch?v=PxcXwk4UHm4>). The second study¹⁶ showed that succinylcholine eliminated the acidosis after the

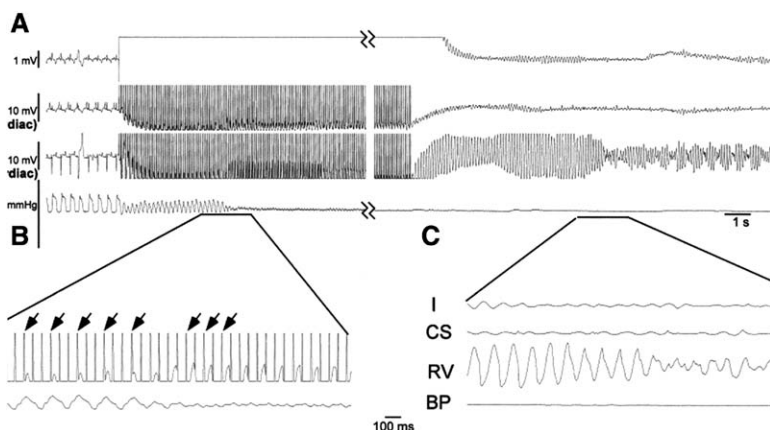


Figure 6. A, Recordings during X26-induced ventricular fibrillation (VF) in a pig while infusing epinephrine. B, Expanded time scale. The **arrowheads at left** depict a 3:1 response to the X26 discharge that progressed to a 2:1 response (**right**), which resulted in **(C)** rapid ventricular tachycardia (VT), degenerating into polymorphic VT and VF. Recordings are surface ECG lead I, intracardiac electrograms from the coronary sinus (CS) and the right ventricular (RV) apex, and blood pressure (BP) from a Millar catheter in the descending aorta. Reproduced from Reference 14 with permission from the publisher. Nanthakumar K, Billingsley IM, Masse S, Dorian P, Cameron D, Chauhan VS, Downar ED, Sevapsidis E. Cardiac electrophysiological consequences of neuromuscular incapacitating device discharges. *J Am Coll Cardiol.* 2006;48:798–804. Copyright © 2006, Elsevier.



Pre- and Post-Discharge EKGs

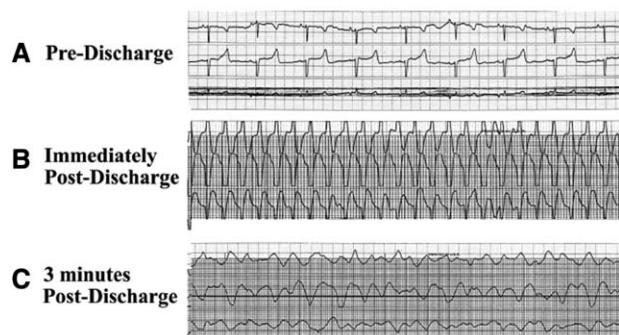


Figure 7. ECGs from a pig taken before (A) and after (B and C) TASER X26 discharge. An initial stable monomorphic ventricular tachycardia was induced after the X26 shock and remained for ≈ 3 minutes before evolving to ventricular fibrillation. Reproduced from Reference 15 with permission from the publisher. Dennis AJ, Valentino DJ, Walter RJ, Nagy KK, Winners J, Bokhari F, Wiley DE, Joseph KT, Roberts RR. Acute effects of Taser X26 discharges in a swine model. *J Trauma*. 2007;63:581–590. Copyright © 2007 Lippincott Williams & Wilkins, Inc.

X26 shock. One pig developed VF after a single 40-second ECD discharge. In the third study,¹⁷ a 10-second TASER X26 discharge induced cardiac capture in 23 of 27 attempts over transcardiac vectors and induced VF in 2 of 4 animals. Nonsustained VT occurred after discharge in the remaining animals. The authors stated:

If our data can be translated to humans, then ventricular rhythm may be captured and postdischarge dysrhythmias or VF may occur. Such transcardiac vectors should be avoided when possible and the potential for deterioration of the cardiac rhythm to VF in the field should be considered....Users should be trained to recognize the possible cardiac effects and be prepared to use automated external defibrillators and cardiopulmonary resuscitation maneuvers when needed.¹⁷

Recent reanalysis¹⁸ of data from the earlier study¹⁴ demonstrated that the average time for cardiac capture was 121 milliseconds (2 impulses from the stun gun), whereas 14 of 38 discharges (37%) captured the heart with the first impulse. The capture rate during discharge accelerated from 4:1 to 3:1 in 7 cases and from 3:1 to 2:1 in 2 cases in an average time of 3.6 seconds. Nonsustained VT followed 4 discharges. Both direct and indirect (via retrograde conduction from captured ventricular beats) atrial capture could occur,¹⁹ and this caused an atrial arrhythmia on 1 occasion. These observations provide support for a 5-second shock being capable of inducing VF and the development of atrial fibrillation after a TASER shock.²⁰

Drive-Stun Capture

Two porcine studies documented cardiac capture after X26 exposure in a drive-stun mode with probes taped to the skin between the suprasternal notch and point of maximal impulse²¹ or 1 dart on the right chest and the other over the left upper abdomen.¹⁷ In

the latter study, darts held $\frac{1}{2}$ in away from the skin by insulating foam blocks were still capable of producing cardiac capture. TASER International states that the high voltage used allows 1 probe to arc through a cumulative 2 in of clothing and not have to physically penetrate the body to have an effect (TASER Instructor Certification Course V-13, May 1, 2006, slide 35).

Thus, much like transthoracic cardiac pacing used emergently to treat bradyarrhythmias in humans,²² pulses from the TASER X26 ECD emit sufficient electric charge to produce transthoracic cardiac capture despite high skin resistance. Because of this, drive-stun application should be capable of causing cardiac capture and VF in humans and was the focus of previous litigation (Williams versus TASER International, Inc; US District Court for the Northern District of Georgia; case No. 06-cv-00051 RWS; filed January 9, 2006). Darts that penetrate the high skin resistance should, in all likelihood, cause cardiac capture even more easily.

Mechanism of Cardiac Arrest

The porcine studies show that the mechanism by which the X26 provokes cardiac arrest is by capturing the heart and increasing its rate to values too rapid for maintenance of organized electric activity, resulting in VT/VF (Figures 6 and 7). Runaway pacemakers years ago produced the same phenomenon,²³ as does rapid pacing during electrophysiological studies. Thus, it should come as no surprise that transcutaneous rapid pacing from an X26 can accomplish the same thing. Ischemia from very low blood pressure could contribute to developing VF. A stimulated ventricular complex falling in the vulnerable period of the previous beat could theoretically induce VT/VF as well. Importantly, animal data (Figures 6 and 7) show that VT can precede the development of VF by seconds to minutes.^{14,15} Therefore, after an X26 shock, an individual could have a palpable pulse for a variable time interval before lapsing into pulseless VT/VF.

Dart-to-Heart Distance

As with all cardiac stimulation, the distance between the stimulating electrodes and the myocardium is critical. When fired, the 2 TASER darts spread at an 8° angle, separating by ≈ 1 ft for every 7 ft of travel,¹ so the distance between 2 impaled darts can be fairly great. According to 1 study, 15 cm was the ideal spread distance for cardiac capture.²¹ Although nonphysiological porcine studies have suggested that dart-to-heart distances of 4 to 17 mm are required to produce VF,^{24,25} TASER ECD shocks with 1 dart in the right chest and the second in the abdomen or right groin, distances exceeding 4 to 17 mm, have been shown to capture the heart in intact pigs¹⁷ and humans.²⁶ Rahko,²⁷ evaluating skin-to-heart distance by echocardiography, stated, “An EMD dart penetrating the skin directly over the heart might put individuals at risk for ventricular fibrillation” and noted that the skin-to-heart distance correlated with BMI. Using the porcine finding²⁴ of 26-mm skin-to-heart distance as a threshold value for individuals

potentially vulnerable to X26-induced VF, he found that 79% of nonobese individuals with BMIs <25 kg/m² were at risk.

In addition to anatomy, body position can influence skin-to-heart distance and therefore dart-to-heart distance. For example, changing positions from upright to prone can shorten the anterior chest-to-heart distance by almost 1 cm (H. Feigenbaum, MD, personal communication, 2013) and facilitate cardiac capture by darts in the anterior chest. Falling prone could drive the darts deeper into the skin. Lying on one's left side brings the heart so close to the chest wall that the apical impulse lies virtually just beneath the skin and is visibly seen and palpated. A dart over the apical impulse would be only a few millimeters from the heart. An enlarged heart could shorten skin-to-heart and therefore dart-to-heart distance. In addition, a state of excitation, for example, adrenaline released during an agitated state of fight or flight, can make the heart more susceptible to cardiac stimulation, which can facilitate capture or VF induction¹⁴ (Figure 6). Because of these variables and the effect of the vector encompassed by the 2 darts,^{13,14,17} in my opinion, no absolute number exists beyond which chest darts could not capture the heart in a particular individual. Darts closest to the cardiac silhouette would pose the greatest risk for cardiac capture and therefore VF induction.

Clinical Research

Multiple clinical studies of varying shock durations, placements, and measurements have not been reported to induce VF. However, because of ethical considerations to protect the volunteers from risk, none of these trials can replicate the actual clinical situation experienced by stressed individuals involuntarily receiving chest ECD shocks in the chaos of a field setting, especially if the shocks are repeated or lengthy. Moscatti et al²⁸ tested supine individuals with 15-second TASER X26 shocks over "leads placed on the right upper chest and right upper abdomen" after alcohol ingestion and found a decrease in pH and bicarbonate and an increase in lactate after alcohol ingestion, with a further increase in lactate (mean, 4.19 mmol/L) and decrease in pH (mean, 7.31) after X26 exposure. No VF resulted. Dawes et al²⁹ studied volunteers with 15-second TASER X26 shocks without probe penetration by taping the conducting wires to the right upper chest and the right upper abdominal quadrant. Core body temperature did not change, and no VF resulted. One subject was excluded because of a history of coronary artery disease with 2 cardiac stents and frequent atrial and ventricular extrasystoles immediately before testing. Apparently, the authors recognized that this individual would be at risk for developing VF. Dawes et al³⁰ tested 5-second TASER X26 shocks delivered to 10 supine subjects (median BMI, 27.5 kg/m²) over implanted chest darts (length not given) during echocardiographic monitoring. Heart rates before (mean, 91.0 bpm), during (mean, 95.8 bpm), and after (mean, 85.7 bpm) shocks did not show capture. The relatively slow mean heart rates are inconsistent with what probably happens during a law-enforcement confrontation in the field.

TASER ECDs can produce cardiac capture in humans. Cao et al³¹ published a case report of a 53-year-old man with

a dual-chamber pacemaker implanted subcutaneously beneath the left clavicle who received 2 X26 shocks with darts in the right chest. Pacemaker interrogation revealed 2 ventricular high-rate episodes that corresponded to the exact time of the X26 shocks. The man was asymptomatic. The ventricular electrograms during X26 cardiac capture were different from those during pacemaker capture, consistent with cardiac capture from the TASER shocks directly from the X26 and not over the pacemaker lead (L. Saxon, MD, personal communication, 2013).

The second study²⁶ tested a new-generation TASER ECD on normal supine human volunteers using echocardiographic monitoring. It demonstrated "an apparent brief episode of cardiac capture" at a rate of 240 bpm during the 10-second TASER ECD shock. The individual had no symptoms during the capture. One dart was slightly to the right of the midline chest with a skin-to-heart distance of 2.57 cm; the second was in the right groin.

Although neither individual developed VF, the fact that a TASER ECD could induce cardiac capture at rates exceeding 200 bpm makes it plausible that, in a given situation and given individual, perhaps in the presence of underlying heart disease such as an old myocardial infarction or a chemical substance such as alcohol or perhaps after longer or repeated shocks or during heightened sympathetic tone, TASER ECD-induced VF becomes possible, as previous authors have suggested.^{13,17,27} Establishing that TASER X26 shocks cannot provoke VF would require replicating potential elements of field situations: testing shocks, some with >15-second duration, with 12- to 14-mm darts over a cardiac vector in multiple upright/prone volunteers, some with heart disease or after ingestion of potentially arrhythmogenic drugs or after receiving epinephrine. Such a study would require anesthetized patients in whom VF induction is necessary for ICD implantation testing.

The videos (Figure 4, Movie I in the [online-only Data Supplement](#), and video at <http://www.youtube.com/watch?v=b6dHpt6c6zM>) in essence show the results of such clinical studies. Although there is no ECG recording or video of the heart, these videos of an "intact human" serve as a substitute for those experiments that cannot be done ethically and show what can happen in real life during a TASER X26 deployment.

Clinical Epidemiology

Several epidemiological studies have not concluded that TASER shocks induced VF. Gardner et al³² reported that 100 shocks in subjects 13 to 17 years old caused no significant injuries. Eastman et al³³ found 1 death in 426 uses that may or may not have been causally related to the ECD. Strote et al³⁴ noted that, of 1101 individuals subjected to M26 and X26 shocks, none died. Bozeman et al³⁵ reported on 1201 uses, almost all X26s. Deaths of 2 subjects were not attributed to electric weapon use because of "prolonged combative behavior, cocaine use, cardiac abnormalities, and possible olanzapine toxicity," questionable reasons to exclude an ECD death. Apparently using the same cohort,¹¹ they noted "no immediate deaths in any cases...to suggest a cardiac dysrhythmia...."

These surveys are too small to exclude a TASER X26 risk of inducing VF. Even so, given the claim by Amnesty International⁶ of 544 deaths associated with ECD use between 2001 and 2013, it is surprising that these studies did not capture at least some of these deaths, which brings their validity into question. Swerdlow et al,³⁶ using an Internet-based search, found 200 cases of ECD-associated, nontraumatic sudden deaths from 2001 to 2008. Thus, more deaths occurred after ECD deployment than captured by the epidemiological studies.

Prior Publications of Cases Consistent With TASER-Induced Cardiac Arrest

Kim and Franklin³⁷ reported that a 14-year-old adolescent shocked with a TASER X26 immediately collapsed and was found by paramedics to be in VF 2 minutes later. Four resuscitative shocks and drug administration restored a perfusing rhythm, and the adolescent made a nearly complete recovery. The ECG published, showing VF terminating after a 360-J defibrillation shock, was not the final shock, but 1 depicting an earlier 200-J shock converting VF to an idioventricular rhythm. Kroll et al³⁸ contested the accuracy of this report, but on the basis of both the paramedic's report and her deposition testimony,³⁹ the allegations of Kroll et al were shown to be incorrect. The paramedic testified that, immediately after the young man lost consciousness, she noted a pulse and respiration but recorded VF about 2 minutes later. A review by the National Institute of Justice⁴⁰ concluded for this case, "The proximity of collapse to CED (conducted energy device) use and documented VF argues in favor of an electrically induced cardiac event."

Another observation is of a 17-year-old boy who received TASER X26 shocks of 25 and 5 seconds in the anterior chest, immediately dropped to the ground, and became cyanotic and apneic.⁴¹ The initial rhythm recorded >10 minutes later was asystole. Resuscitation included hypothermia, and he survived with memory impairment.

Of the 200 deaths analyzed by Swerdlow et al,³⁶ 56 subjects collapsed within 15 minutes of the ECD shock and had the presenting rhythm reported. Four had VF and 52 had bradycardia/asystole or pulseless electric activity. Swerdlow et al concluded that 1 death was typical of electrically induced VF and stated,

For subject 1, who collapsed immediately...neither drugs nor cardiac disease can be implicated; both the time course and the electrode location are consistent with electrically induced VF." They continued, "To the best of our knowledge, this is the first reported fatality suggestive of [ECD]-induced VF.

Role of Underlying Heart Disease

Some of the TASER X26 ECD-induced cardiac arrests occurred in individuals alleged to have structurally abnormal hearts or in the presence of potentially arrhythmogenic substances such as alcohol.² Invasive electrophysiological testing over many years has demonstrated that it is easier to

electrically induce VF when the heart is abnormal or in the presence of arrhythmogenic substances.⁴² So, rather than preclude a diagnosis of X26-induced cardiac arrest in such a setting, the presence of these abnormalities actually helps support that diagnosis. Arguments suggesting that heart disease or a chemical substance, not the ECD shock, caused the cardiac arrest must require that coincidentally at the exact time of the TASER shock, the underlying heart disease or drugs triggered the VF, an unlikely assumption. Some individuals may have pacemakers³¹ or defibrillators⁴³ in place, and they can be at risk for device-device interactions.


Importance of Vital Signs and Movement During VT/VF

Most observers, including physicians, rarely witness a person dying of VT/VF without intervening and do not know what to expect in terms of body movement, pulse, or respiration. In the unfortunate death of basketball player Hank Gathers resulting from exercise-induced VT captured on video, almost a full minute elapsed from the time he fell on court, presumably from a syncopal episode, until he finally stopped moving. He exhibited apparently purposeful movements, including sitting up, and breathing until finally succumbing to VF (www.youtube.com/watch?v=vcD5XUXfr1Y). Thus, claiming that a death cannot be due to VT/VF resulting from a TASER X26 shock because the individual was breathing or moving seconds or even minutes after the shock, when there can be no other cause for the sudden loss of consciousness in an individual who was alert and functioning immediately before the X26 shock, is without merit.

Multiple explanations exist for such events. First, VT before VF, as noted in several pig experiments¹⁵ (Figures 6 and 7), could provide sufficient cerebral blood flow to maintain some bodily functions. In fact, in the case noted earlier,^{37,39} the paramedic present during the entire TASER X26 deployment stated in sworn deposition testimony that she counted a pulse of 100 bpm over 15 seconds and respirations of 16 breaths per minute immediately after the TASER X26 ECD shock when the individual was totally unconscious, with VF established by ECG 2 minutes later (explained if VT with a pulse preceded the VF).

Second, normal breathing has been documented in sheep and pigs for as long as 1 minute and in humans for at least the first 12 to 15 seconds after the onset of VF.^{44,45} Therefore, normal respirations can continue despite VF. Furthermore, confusing agonal respirations with normal respirations, especially early after VF onset, can confound the interpretation of the events.

Finally, accurate palpation of a pulse, particularly a radial pulse, in the midst of the turmoil of observing an unresponsive subject after a police altercation can be inaccurate. In a test among first responders checking a carotid pulse in patients before and while undergoing cardiopulmonary bypass, when no pulse was present, 10% (6 of 59) did not recognize an absent carotid pulse. In fact, only 1 in 59 emergency medical technicians and paramedics identified pulselessness correctly in 10 seconds, making the authors conclude that "...recognition of pulselessness by rescuers with basic CPR training is time-consuming and inaccurate."⁴⁶



In a study using a computerized mannequin, 64 experienced healthcare providers checked the carotid pulse for 10 or 30 seconds. When there was no pulse, 27 of 42 responders checking for 10 seconds said there was a pulse, and 32 of 50 said there was a pulse after checking for 30 seconds. The authors stated,

If the absence of a pulse was the only factor determining the onset of CPR maneuvers, approximately 50% of pulseless patients simulated in our study would not have had CPR initiated.⁴⁷

Excited Delirium

Excited delirium has been reported as the cause of TASER X26-related deaths as a result of an agitated and irrational state, usually compounded by physical restraint. The diagnosis of excited delirium is not recognized by the American Medical Association as a medical or psychiatric condition but is recognized by the National Association of Medical Examiners. Many of the individuals dying with this alleged diagnosis have taken stimulant drugs such as phencyclidine, methamphetamine, and cocaine or have suffered from severe mental illness, were restrained with hands bound behind them and legs shackled, and held prone on the ground, making breathing difficult. Drug toxicity or postural hypoxia or anoxia has been appropriately suggested as contributing to death in many of these individuals. The presence of increased body temperature is said to be an important differentiator of excited delirium from other causes of death⁴⁸; however, “the exact signs and symptoms [of excited delirium] are difficult to define precisely, . . .”⁴⁹ thus hampering an accurate diagnosis. It is possible that excited delirium is a form of takotsubo syndrome,^{50,51} which might be a cause of some in-custody deaths. However, as noted above, to attribute an ECD death to excited delirium, one must postulate that the excited delirium, if the entity exists, caused VF at the precise time of the TASER shock.

Asystole

Untreated, VF evolves to asystole, sometimes in as short as 3 minutes⁵² but usually longer,⁵³ and has been noted in some patients after ECD-related collapse^{2,36} (Table and Figures 3 and 5). Waalewijn et al⁵⁴ analyzed 873 patients and found the probability to record VF decreased per minute and the probability of asystole increased as time from collapse elapsed. At 10 minutes, the probability of asystole without basic life support is $\approx 25\%$, rising to $\approx 35\%$ at 15 minutes. Therefore, recording asystole after a prolonged “down time” following X26 administration does not exonerate the X26 from causing the death.

Causality

A temporal association alone does not prove causality. However, when the following exist, in my opinion, a causal relationship between the TASER X26 ECD and cardiac arrest in humans is established: (1) known causal mechanism (cardiac capture at rapid rates), (2) temporal association with loss of consciousness and subsequent cardiac arrest (TASER shock precedes both), (3) recorded VF (or asystole if a prolonged interval until first ECG;

biological mechanism), (4) TASER shock(s) with 1 or both chest barbs near the heart (required for cardiac capture), (5) no other plausible alternative explanation (normal heart or underlying heart disease/drugs, if present, unlikely to cause VF at that precise time), and (6) similar cases in the literature (see above).

Conclusions and Recommendations

The animal and clinical data clearly support the conclusion that a TASER X26 shock can produce VF in humans by the mechanisms elaborated above. Although the risk may be low, its number cannot be known without universal record keeping and the creation of a national database. Because of this risk, it has been suggested that law-enforcement experts reassess ECD use to maintain a balance of safety for subjects and officers while still achieving the goal of maintaining law and order.⁵⁵ In this regard, the Cincinnati Police Department has revised its use-of-force policy to ban TASER chest shots except in self-defense or the defense of another.⁵⁶

The use of TASERS may be increasing. A recent *Guardian* article indicated that the deployment of TASER weapons has more than doubled in England and Wales, from ≈ 3500 in 2009 to 14 500 in 2010 and 2011.⁵⁷ In addition, a new TASER ECD, the X2, capable of shooting 2 cartridges, has been tested in 4 pigs exposed to 5-second shocks; it produced cardiac capture in 17 of 71 exposures (24%) at heart rates of 206 to 313 bpm compared with X26 capture in 45 of 71 exposures (63%) at heart rates of 180 to 313 bpm.⁵⁸ No pig developed VF. The authors concluded that the “transcardiac” pathway was less important for capture than the proximity of the dart to the heart.

I think ECD manufacturers should undertake an educational campaign to make all ECD users aware of the VF risk. Educational material should stress avoiding chest shots if possible and should warn against repeated or long trigger pulls. However, it is clear that a single 5-second shock can induce VF. A user should be judicious with ECD deployment and treat it with the same level of respect as a firearm, suspect cardiac arrest in any individual who becomes unresponsive after a shock, quickly call for medical support, and be prepared to resuscitate, including using an automated external defibrillator if needed. A national database should be mandated.

Acknowledgments

I thank John Burton, Esq, and M. Joan Zipes for reviewing the manuscript.

Source of Funding

This work was supported by the Krannert Institute of Cardiology Charitable Trust.


Disclosures

The Institutional Review Board of the Indiana University School of Medicine approved the medical information used for this article. Written informed consent was obtained from each person or an authorized representative. The cases included have been studied as part of litigation related to administration of ECD shocks from the TASER X26 device. I have served (and in the future may serve) as a paid

plaintiff expert witness in ECD-related sudden cardiac arrest/death cases. Despite this conflict of interest, I have tried to present the salient facts about the cases and to offer scientific evidence, credible argument, and logic to support the conclusions. Statements in this manuscript are my opinion, made to a reasonable degree of medical certainty.

References

1. TASER Electronic © 2009; TASER International, Inc. Control Devices Electrical Characteristics-X26. February 1, 2009.
2. Zipes DP. Sudden cardiac arrest and death following application of shocks from a TASER electronic control device [erratum appears in *Circulation*. 2012;125:e27]. *Circulation*. 2012;125:2417–2422.
3. Myerburg RJ, Goodman KW, Ringe TB 3rd. Electronic control devices: science, law, and social responsibility. *Circulation*. 2012;125:2406–2408.
4. Zipes DP. Response to letters regarding article, “sudden cardiac arrest and death following application of shocks from a TASER electronic control device.” *Circulation*. 2013;127:e261–e262.
5. USA: “Less Than Lethal”? List of Deaths Following Use of Stun Weapons in US Law Enforcement: 3 June 2001 to 31 August 2008. New York, NY: Amnesty International Publications; December 16, 2008. Index No. AMR 51/010/2008.
6. Electronic Village Blog. <http://electronicvillage.blogspot.com/2009/05/taser-related-deaths-in-united-states.html>. Accessed August 23, 2013.
7. TASER X26 electronic control device user course version. May 1, 2006.
8. TASER Training Bulletin 15.0. Medical research update and revised warnings. September 30, 2009.
9. TASER 2011 instructor and user warnings, risks, liability release, and covenant not to sue. May 31, 2011.
10. Brave M. Liability Assessment Awareness International, Inc. April 9, 2012.
11. Bozeman WP, Teacher E, Winslow JE. Transcardiac conducted electrical weapon (TASER) probe deployments: incidence and outcomes. *J Emerg Med*. 2012;43:970–975.
12. Malik S, Mole C. Police continued to fire Tasers at chests—despite cardiac arrest warnings. *The Guardian*. July 14, 2013. <http://www.theguardian.com/uk-news/2013/jul/14/police-tasers-cardiac-arrest-warnings>. Accessed August 23, 2013.
13. Lakkireddy D, Wallick D, Ryschon K, Chung MK, Butany J, Martin D, Saliba W, Kowalewski W, Natale A, Tchou PJ. Effects of cocaine intoxication on the threshold for stun gun induction of ventricular fibrillation. *J Am Coll Cardiol*. 2006;48:805–811.
14. Nanthakumar K, Billingsley IM, Masse S, Dorian P, Cameron D, Chauhan VS, Downar E, Sevapsidis E. Cardiac electrophysiological consequences of neuromuscular incapacitating device discharges. *J Am Coll Cardiol*. 2006;48:798–804.
15. Dennis AJ, Valentino DJ, Walter RJ, Nagy KK, Winners J, Bokhari F, Wiley DE, Joseph KT, Roberts RR. Acute effects of TASER X26 discharges in a swine model. *J Trauma*. 2007;63:581–590.
16. Walter RJ, Dennis AJ, Valentino DJ, Margeta B, Nagy KK, Bokhari F, Wiley DE, Joseph KT, Roberts RR. TASER X26 discharges in swine produce potentially fatal ventricular arrhythmias. *Acad Emerg Med*. 2008;15:66–73.
17. Valentino DJ, Walter RJ, Dennis AJ, Margeta B, Starr F, Nagy KK, Bokhari F, Wiley DE, Joseph KT, Roberts RR. Taser X26 discharges in swine: ventricular rhythm capture is dependent on discharge vector. *J Trauma*. 2008;65:1478–1486.
18. Masse S, Desfosses-Masse J, Hado H, Waxman MB, Nanthakumar K. Determining the safe duration for stun gun discharge across the chest. *Heart Rhythm*. 2013;10:S186.
19. Hado HS, Masse S, Das M, Gizurarson S, Khan F, Roshn J, Waxman M, Nanthakumar K. The effect of stun gun discharges on the atrium. *Heart Rhythm* 2013; 10:S404.
20. Multerer S, Berkenbosch JW, Das B, Johnsrude C. Atrial fibrillation after taser exposure in a previously healthy adolescent. *Pediatr Emerg Care*. 2009;25:851–853.
21. Lakkireddy D, Wallick D, Verma A, Ryschon K, Kowalewski W, Wazni O, Butany J, Martin D, Tchou PJ. Cardiac effects of electrical stun guns: does position of barbs contact make a difference? *Pacing Clin Electrophysiol*. 2008;31:398–408.
22. Sherbino J, Verbeek PR, MacDonald RD, Sawadsky BV, McDonald AC, Morrison LJ. Prehospital transcutaneous cardiac pacing for symptomatic bradycardia or bradyasystolic cardiac arrest: a systematic review. *Resuscitation*. 2006;70:193–200.
23. Nasrallah A, Hall RJ, Garcia E, Kyger ER, Hallman GL, Cooley DA. Runaway pacemaker in seven patients: a persisting problem. *J Thorac Cardiovasc Surg*. 1975;69:365–368.
24. Wu JY, Sun H, O'Rourke AP, Huebner S, Rahko PS, Will JA, Webster JG. Taser dart-to-heart distance that causes ventricular fibrillation in pigs. *IEEE Trans Biomed Eng*. 2007;54:503–508.
25. Wu JY, Sun H, O'Rourke AP, Huebner SM, Rahko PS, Will JA, Webster JG. Taser blunt probe dart-to-heart distance causing ventricular fibrillation in pigs. *IEEE Trans Biomed Eng*. 2008;55:2768–2771.
26. Ho JD, Dawes DM, Reardon RF, Strote SR, Kunz SN, Nelson RS, Lundin EJ, Orozco BS, Miner JR. Human cardiovascular effects of a new generation conducted electrical weapon. *Forensic Sci Int*. 2011;204:50–57.
27. Rahko PS. Evaluation of the skin-to-heart distance in the standing adult by two-dimensional echocardiography. *J Am Soc Echocardiogr*. 2008;21:761–764.
28. Moscati R, Ho JD, Dawes DM, Miner JR. Physiologic effects of prolonged conducted electrical weapon discharge in ethanol-intoxicated adults. *Am J Emerg Med*. 2010;28:582–587.
29. Dawes DM, Ho JD, Johnson MA, Lundin E, Janchar TA, Miner JR. 15-Second conducted electrical weapon exposure does not cause core temperature elevation in non-environmentally stressed resting adults. *Forensic Sci Int*. 2008;176:253–257.
30. Dawes DM, Ho JD, Reardon RF, Miner JR. Echocardiographic evaluation of TASER X26 probe deployment into the chests of human volunteers. *Am J Emerg Med*. 2010;28:49–55.
31. Cao M, Shinbane JS, Gillberg JM, Saxon LA, Swerdlow CD. Taser-induced rapid ventricular myocardial capture demonstrated by pacemaker intracardiac electrograms. *J Cardiovasc Electrophysiol*. 2007;18:876–879.
32. Gardner AR, Hauda WE 2nd, Bozeman WP. Conducted electrical weapon (TASER) use against minors: a shocking analysis. *Pediatr Emerg Care*. 2012;28:873–877.
33. Eastman AL, Metzger JC, Pepe PE, Benitez FL, Decker J, Rinnert KJ, Field CA, Friese RS. Conductive electrical devices: a prospective, population-based study of the medical safety of law enforcement use. *J Trauma*. 2008;64:1567–1572.
34. Strote J, Walsh M, Angelidis M, Basta A, Hutson HR. Conducted electrical weapon use by law enforcement: an evaluation of safety and injury. *J Trauma*. 2010;68:1239–1246.
35. Bozeman WP, Hauda WE 2nd, Heck JJ, Graham DD Jr, Martin BP, Winslow JE. Safety and injury profile of conducted electrical weapons used by law enforcement officers against criminal suspects. *Ann Emerg Med*. 2009;53:480–489.
36. Swerdlow CD, Fishbein MC, Chaman L, Lakkireddy DR, Tchou P. Presenting rhythm in sudden deaths temporally proximate to discharge of TASER conducted electrical weapons. *Acad Emerg Med*. 2009;16:726–739.
37. Kim PJ, Franklin WH. Ventricular fibrillation after stun-gun discharge: letter to the editor. *New Engl J Med*. 2005;353:958–959.
38. Kroll MW, Calkins H, Luceri RM. Letter to the editor. *J Am Coll Cardiol*. 2007;49:732.
39. Hutchison J. Deposition in Circuit Court of Cook County, 21 June, 2007. *Ortega-Piron v Lopez*. 05 L 1643.
40. Study of Deaths Following Electro Muscular Disruption: NIJ Report. Washington, DC: US Department of Justice, Office of Justice Programs; May 2011.
41. Schwarz ES, Barra M, Liao MM. Successful resuscitation of a patient in asystole after a TASER injury using a hypothermia protocol. *Am J Emerg Med*. 2009;27:515.e1–515.e2.
42. Greenspon AJ, Stang JM, Lewis RP, Schaal SF. Provocation of ventricular tachycardia after consumption of alcohol. *N Engl J Med*. 1979;301:1049–1050.
43. Haegeli LM, Sterns LD, Adam DC, Leather RA. Effect of a Taser shot to the chest of a patient with an implantable defibrillator. *Heart Rhythm*. 2006;3:339–341.
44. Zuercher M, Ewy GA, Hilwig RW, Sanders AB, Otto CW, Berg RA, Kern KB. Continued breathing followed by gasping or apnea in a swine model of ventricular fibrillation cardiac arrest. *BMC Cardiovasc Disord*. 2010;10:36.
45. Haouzi P, Ahmadpour N, Bell HJ, Artman S, Banchs J, Samii S, Gonzalez M, Gleeson K. Breathing patterns during cardiac arrest. *J Appl Physiol (1985)*. 2010;109:405–411.

- 
46. Eberle B, Dick WF, Schneider T, Wissner G, Doetsch S, Tzanova I. Checking the carotid pulse check: diagnostic accuracy of first responders in patients with and without a pulse. *Resuscitation*. 1996;33:107–116.
47. Lapostolle F, Le Toumelin P, Agostinucci JM, Catineau J, Adnet F. Basic cardiac life support providers checking the carotid pulse: performance, degree of conviction, and influencing factors. *Acad Emerg Med*. 2004;11:878–880.
48. Jauchem JR. Pathophysiologic changes due to TASER® devices versus excited delirium: potential relevance to deaths-in-custody? *J Forensic Leg Med*. 2011;18:145–153.
49. Vilke GM, Bozeman WP, Dawes DM, Demers G, Wilson MP. Excited delirium syndrome (ExDS): treatment options and considerations. *J Forensic Leg Med*. 2012;19:117–121.
50. Wittstein IS, Thiemann DR, Lima JA, Baughman KL, Schulman SP, Gerstenblith G, Wu KC, Rade JJ, Bivalacqua TJ, Champion HC. Neurohumoral features of myocardial stunning due to sudden emotional stress. *N Engl J Med*. 2005;352:539–548.
51. Madias C, Fitzgibbons TP, Alsheikh-Ali AA, Bouchard JL, Kalsmith B, Garlitski AC, Tighe DA, Estes NA 3rd, Aurigemma GP, Link MS. Acquired long QT syndrome from stress cardiomyopathy is associated with ventricular arrhythmias and torsades de pointes. *Heart Rhythm*. 2011;8:555–561.
52. Dubrey SW, Grocott-Mason R. Spontaneous recovery from prolonged cardiac arrest. *Heart*. 2002; 87:432.
53. Hallstrom AP, Eisenberg MS, Bergner L. The persistence of ventricular fibrillation and its implication for evaluating EMS. *Emerg Health Serv Q*. 1982;1:41–49.
54. Waalewijn RA, Nijpels MA, Tijssen JG, Koster RW. Prevention of deterioration of ventricular fibrillation by basic life support during out-of-hospital cardiac arrest. *Resuscitation*. 2002;54:31–36.
55. Miller ME. Taser use and the use-of-force continuum: examining the effect of policy change. *The Police Chief*. 2010; 77: 72–76.
56. O’Keefe PJ. Cincinnati police revises use of force policy, specifically with use of Tasers. September 18, 2012. <http://www.wcpo.com/news/local-news/cincinnati-police-revises-use-of-force-policy-specifically-with-use-of-tasers>. Accessed August 23, 2013.
57. Laville S. *The Guardian*. September 8, 2013. <http://www.theguardian.com/uk-news/2013/sep/08/police-use-tasers-doubles-year>. Accessed September 8, 2013.
58. Dawes DM, Ho JD, Moore JC, Miner JR. An evaluation of two conducted electrical weapons and two probe designs using a swine comparative cardiac safety model. *Forensic Sci Med Pathol*. 2013;9:333–342.

Response to Zipes

Mark W. Kroll, PhD; Dhanunjaya R. Lakkireddy, MD; James R. Stone, MD, PhD; Richard M. Luceri, MD

In controversies like this, transparency, absence of conflict, and adherence to the scientific method are important requisites. In Dr Zipes’ series, not a single medical examiner postulated the ECD as the primary cause of death. The presumably unbiased Council of Canadian Academies report (<http://www.caahs-acss.ca/the-health-effects-of-conducted-energy-weapons-2/>) concluded that Dr Zipes’ “study...is particularly questionable” and stated that “In the [$>2\,000\,000$ ECD uses in the] field there has not been a conclusive case of fatal ventricular fibrillation caused solely by the electrical effects....A small number of human cases have found a temporal relationship between [ECDs] and fatal cardiac arrhythmias but they do not allow for confirmation or exclusion of a clear causal link....” Dr Zipes cites Sherbino to support his claim that the ECD charge is equivalent to that of transcutaneous pacing; however, Sherbino does not report any pacing thresholds. Zipes himself, with Klein as first author, reports thresholds of 2440 microcoulombs (61 mA·40 ms)—significantly greater than the 100 microcoulombs of the ECD. The temporal coincidence argument is discussed in our article and online-only Data Supplement and is refuted by Dr Zipes’ case 4 (our case 8) in which the probes missed the subject. Dr Zipes may also be confusing the sensitivity of a pulse finding (which is low) with its specificity (which is high). The assertion of a “precise” timing (between the ECD and cardiac arrest) may be ill advised when the majority of cases had a documented pulse, normal breathing for 6.1 ± 3.1 minutes, and abnormal underlying cardiac morphology.